

CASE REPORT

Hand Assisted Laparoscopic Splenectomy (HALS) in a Case of Primary Solitary Unilocular Giant Splenic Hydatid

Rayees Syed, Shagun Mahajan, Bhumika, R. K. Chrungoo

Abstract

Hydatid disease, a zoonotic parasitic infestation mainly caused by *Echinococcus granulosus* is a significant problem in endemic areas. Primary splenic hydatidosis is rare. A case is described in a 52 year male who presented with left upper quadrant swelling and pain. Ultrasonography of the abdomen revealed enlarged spleen with span of 14 cm with intraparenchymal cyst measuring 93.1mm x 92.3mm x 83.3mm with approximate volume of 378.3 cc. CT scan of the abdomen showed spleen enlarged in size and measures 14.1cm with well defined cystic lesion of 10.1 x 9.2 cm. cyst shows internal serpentine structure suggestive of membranes with no calcification and no liver involvement. Hand assisted laparoscopic splenectomy (HALS) was performed.

Key Words

Echinococcus, HALS, Hydatidosis

Introduction

Hydatidosis is a disease of ancient times. In 1790 it was Berlott who did a commendable job by detecting and describing splenic hydatidosis as an autopsy finding. (1) It may present as non specific complaint or else detected incidentally. Prepondrance is present in cattle rearing areas of South America, Middle East, South Europe, India. Splenic hydatid has worldwide incidence of 0.5-4% with highest incidence in Iran. (2, 3) Although it may involve any soft tissue or organ, spleen (5.1%) is the third commonest site following liver (75%) and lung (15.4%). (4) It may rarely be encountered in kidney, bone, thyroid, breast pancreas, CNS, orbit, psoas muscle but rarely present in childhood. (5) Most of the hydatid cysts are acquired in childhood but a latent period of 5-25 years occurs before diagnosis is made, this accounts for hydatid

cysts in children being rare. By a very crude estimate the hydatid cyst increases in diameter by about 2-3 cm each year. The rate of growth of hydatid cyst is dependent on immunologic relationship between the parasite and human. Humans are accidental intermediate hosts in the cycle of *Echinococcus* infestation. After ingestion, the eggs hatch and oncospheres penetrate intestinal mucosa and the circulation. Embryos are carried to the liver to be arrested in the sinusoidal capillaries (first filters), some of the embryos pass through the hepatic capillaries and enter the pulmonary circulation and filter out in lungs (second filter). Few embryos pass through the pulmonary capillaries and enter general blood stream and get lodged at various organs, hence posing diagnostic dilemmas. Liver and lungs are commonly affected but primary infestation of spleen is rather rare.

From the Department of Surgery, ASCOMS Sidra, Jammu J&K India

Correspondence to : Dr. R Charangoo, Professor of Surgery, Department of Surgery ASCOMS Sidra, Jammu J&K India

Fig.1 Showing Intraparenchymal Cyst

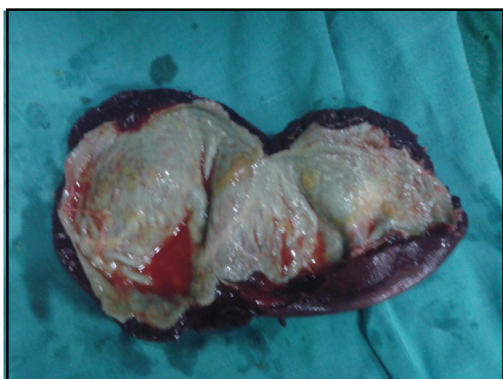

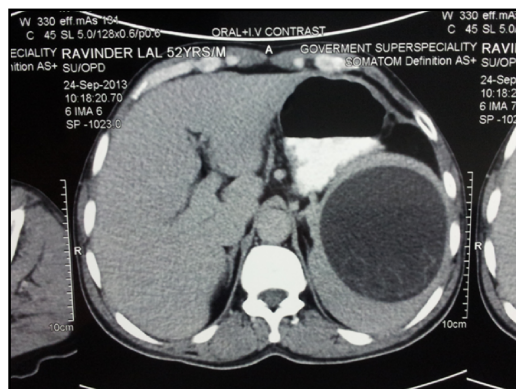
Fig.1 Intraparenchymal cyst measuring 93.1mm x 92 3mm x83.3mm with approximate volume of 378.3 cc

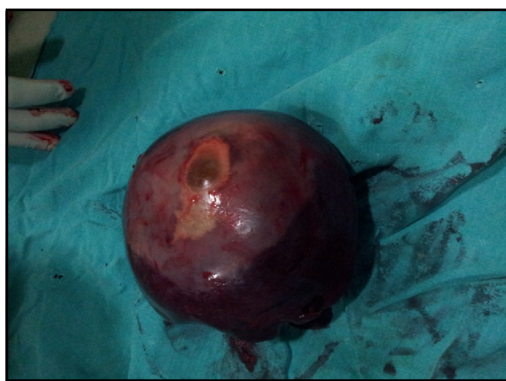

Fig.2 Showing Hand Assisted Laparoscopic Splenectomy

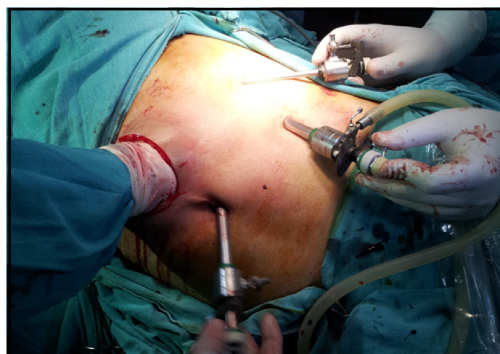

Fig.4 Showing CT scan of the abdomen showed spleen enlarged in size and measured 14.1cm with well defined cystic lesion of 10.1 x 9.2 cm



Case Report

A 52 years old male cultivator from rural area of Jammu, J&K, India with no significant past medical history presented with history of two months progressively increasing upper abdomen swelling and dull aching pain. Patient also complained of occasional nausea, vomiting and generalized weakness. There was no history of jaundice, distress, weight loss. Vitals and general physical examination of the patient was normal. Abdominal examination revealed splenomegaly with smooth surface and mild tenderness. Routine investigation CBC showed raised eosinophil count while as coagulation profile, biochemistry kidney function test (KFT) and liver function tests (LFT), serum electrolytes revealed no abnormality. ESR was 62mm/hr. Plain radiograph of abdomen revealed a well defined, rounded soft tissue opacity with no calcification. Abdominal sonogram

revealed enlarged spleen with span of 14 cm with intraparenchymal cyst measuring 93.1mm x 92 3mm x83.3mm with approximate volume of 378.3 cc. CT scan of the abdomen showed spleen enlarged in size and measured 14.1cm with well defined cystic lesion of 10.1 x 9.2 cm. cyst showed internal serpentine structure suggestive of membranes with no calcification and no liver involvement. Serology tests were positive for hydatid disease. Operative treatment was done by performing a hand assisted laparoscopic splenectomy (HALS) with three instrument ports and a 4 to 6 cm supraumbilical port for hand assisted manipulation and removal of spleen.

Discussion

Echinococcosis has a worldwide preponderance. The infestation is characterized by presence of a definitive host and an intermediate host. Dog is the definitive host and sheep, cattle, goats and human are intermediate ones.

On consumption of infested beef or lamb, humans ingest eggs, embryos and the eggs penetrate intestinal mucosa and enter portal circulation and may get lodged in any part of body. (6) Approximately two- third of hydatid cysts develop in the liver, one-fifth in the lungs and remaining in other organs. Cyst grows at a rate of 1-3 cm/year. Primary infestation of the spleen occurs by the arterial route after the parasite passes the two filters (hepatic and pulmonary). A retrograde venous route which also bypasses the lung and liver is also described. (7) .Secondary splenic hydatid occurs due to disseminated or intraperitoneal spread from ruptured hydatid cyst. (8)

Splenic hydatid cyst is usually asymptomatic, solitary, slow growing and incidentally diagnosed. These are usually asymptomatic but may present with painful mass in the left upper abdomen. Its complications are due to compression, infection, intra-abdominal rupture, anaphylaxis and secondary hydatidosis. Tarcoveanu E . (9) reported 38 cases of splenic hydatidosis and abdominal pain was the most common symptom among these. It has been reported to complicate as fistula into the bowel mainly colon leading to pain and life threatening pericystic inflammation. Teke *et al* (10) reported splenic hydatid perforation into left colon leading to massive gastrointestinal bleed. Rupture into thorax leads to spleno thoracic fistula. Severe anaphylaxis due to rupture leads to fever, pruritis, stridor, dyspnoea and odema. Open splenectomy has been the traditional treatment of choice for hydatid cyst for decades as it was thought to be simple and safe. (11) Laparoscopic management too however is safe and effective alternative to open (12) and it reduces the incision size, bleeding and has better cosmetic results with all advantages of minimally invasive surgery especially early return to work. In our case we performed hand assisted laparoscopic splenectomy. Post operative period of this patient was uneventful.

Conclusion

The infrequency with which it is encountered makes early diagnosis of splenic hydatid rather challenging especially in non endemic areas..It should be considered as a differential diagnosis of all cystic masses in the spleen. Preoperative evaluation needs to be carried out carefully. CT scan is the investigation of choice. Although

the management must be individualized for each patient, a laparoscopic or laparoscopy assisted surgical resection is the best curative procedure in all respects. Post surgical treatment is necessary to ensure complete healing and avoid complications of splenectomy.

References

1. Muro j, Ortiz-Vazquez J, Mino G, Sanmartin P. Angiographic localization of hydatid cyst of spleen. *Rev Clin Esp* 1969;115:433-8
2. Humphreys WG, Johnston GW. Splenic cysts: A review of 6 cases. *Br J Surg* 1979;66:407-8.
3. Torbati M. Hydatid disease of the spleen. Report of an unusual case. *Br J Surg* 1972;59:489-91.
4. Safioleas M, Misiakos E, Manti C. Surgical treatment for splenic hydatidosis. *World J Surg* 1997;21:374-7.
5. Chrungoo RK *et al*. Hydatid disease in children. *JIMA* 1984;82:250-251.
6. Pezeskhi A, Kia AB, Gholizadeh A, Koohzare A. An analysis of hydatid cyst surgeries in Tehran Milad hospital, IRAN during 2001-2004. *Pak J Med Sci* 2007;23:138-40.
7. Miguel AC, Ernesto GV, Adriana AP, Raquel PA. A giant splenic hydatid cyst case presented with dyspnoea and fever. *Medcrit* 2009;6:54-7.
8. Sahu SK, Srivastava R, Sachan PK, Bahl DV. Primary Hydatid Cyst of spleen : A Case site of presentation. *Internet J Surgery* 2008;14:1
9. Tarcoveanu E, Pleasa A, Danila N, Lupascu C, Cotea E. Splenic hydatid cyst, observation upon 38 cases of splenic echinococcosis *Rev Med Chir Soc Med Nat Iasi* 2002;107(2):311-5.
10. Teke Z, AB Yagci, AO Atalay, B Kabay. Splenic hydatid cyst perforating into colon manifesting as massive lower gut bleed: an unusual case of disseminated abdominal echinococcosis. *Singapore Med J* 2008;49(5):e113-6.
11. Dar MA, Shah OJ, Wani NA, Khan FA, Shah P. Surgical management of splenic hydatidosis. *Surg Today* 2002;32:224-9
12. Khoury G . Laparoscopic treatment of hydatid cysts of liver and spleen. *Surg Endosc* 2000;14:243-45.